

Molecular and Histopathological Study on the Ameliorative Effects of Curcumin Against Lead Acetate-Induced Hepatotoxicity and Nephrototoxicity in Wistar Rats

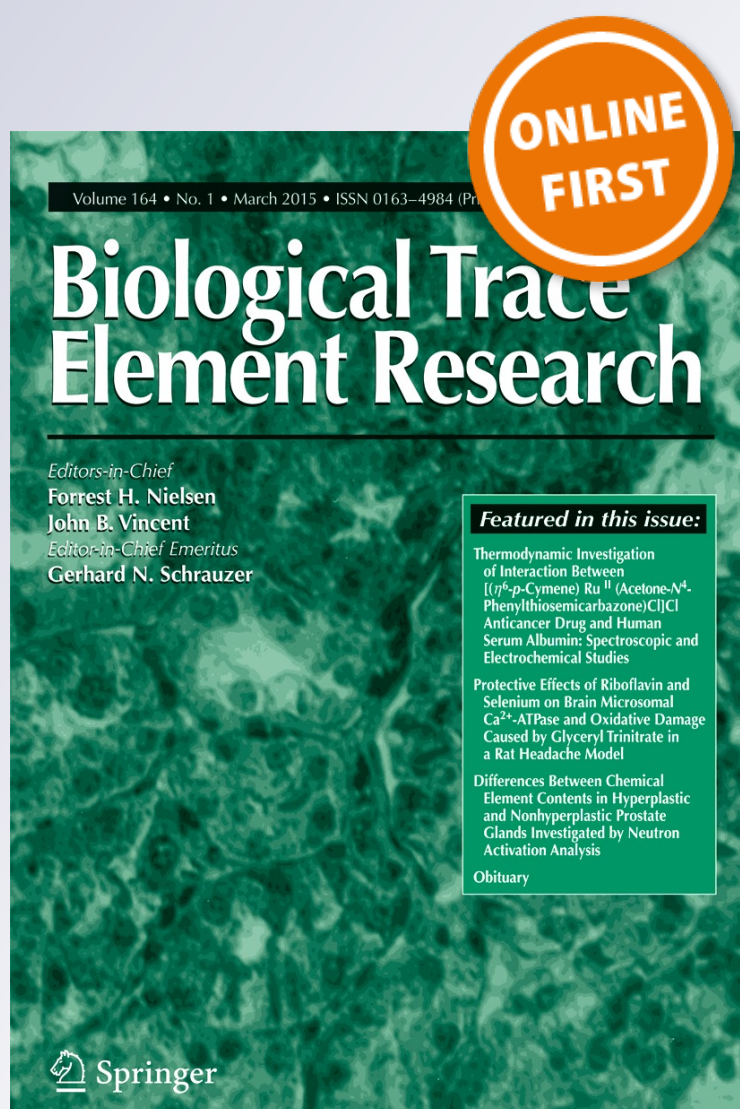Mohamed M. Soliman, Ahmed A. Baiomy & Magdy H. Yassin

Biological Trace Element Research

ISSN 0163-4984

Biol Trace Elem Res

DOI 10.1007/s12011-015-0280-0



Your article is protected by copyright and all rights are held exclusively by Springer Science +Business Media New York. This e-offprint is for personal use only and shall not be self-archived in electronic repositories. If you wish to self-archive your article, please use the accepted manuscript version for posting on your own website. You may further deposit the accepted manuscript version in any repository, provided it is only made publicly available 12 months after official publication or later and provided acknowledgement is given to the original source of publication and a link is inserted to the published article on Springer's website. The link must be accompanied by the following text: "The final publication is available at link.springer.com".

Molecular and Histopathological Study on the Ameliorative Effects of Curcumin Against Lead Acetate-Induced Hepatotoxicity and Nephrototoxicity in Wistar Rats

Mohamed M. Soliman · Ahmed A. Baiomy ·
Magdy H. Yassin

Received: 20 December 2014 / Accepted: 23 February 2015
© Springer Science+Business Media New York 2015

Abstract Lead (Pb^{2+}) toxicity is the most common form of heavy metal intoxication in humans and animals. Therefore, the current study was conducted to evaluate the potential ameliorative effects of curcumin on lead acetate (LA)-induced deleterious effects in the liver and kidney. Forty male Wistar rats were divided into four equal groups; first group was used as a control and given both corn oil orally and vehicle of lead acetate intraperitoneally (i.p). Groups from 2–4 were treated with lead acetate (LA; 50 mg/kg BW i.p), curcumin (200 mg/kg BW orally), and curcumin plus lead acetate, respectively. Curcumin was administered 3 weeks before LA injection for 7 days. Pb^{2+} -intoxicated rats have higher Pb^{2+} levels compared to other treated groups. Results revealed that lead acetate significantly increased the serum levels of

hepatic transaminases (GPT and GOT), urea and creatinine, while albumin was significantly decreased. In parallel, serum IgG, IgM, and IgA were significantly decreased in LA-injected rats. LA groups showed decrease in messenger RNA (mRNA) expression of catalase, SOD, GST, GPx, and alpha-1 acid glycoprotein (AGP), while the gene expression of desmin, vimentin, transforming growth factor- β 1 (TGF- β 1), monocyte chemoattractant protein-1 (MCP-1), and alpha-2 macroglobulin (α -2M) was increased. Prior and coadministration of curcumin with LA for 7 days significantly improved the ameliorated changes in liver and kidney, immunoglobulins, and mRNA expression. Moreover, curcumin ameliorated LA-induced congestion of hepatic and renal blood vessels and decreased fibrous tissue proliferation and necrosis of hepatocytes. In the kidney, LA-induced degeneration in tubular epithelium and intraluminal hyaline casts and prior curcumin administration restored normal renal structure with mild congestion of renal blood vessels. The results clarify the potential of curcumin to counteract the immunosuppressive alteration in gene expression as well as hepatic and renal damage occurred after Pb^{2+} intoxication.

M. M. Soliman
Medical Laboratory Department, Faculty of Applied Medical Sciences, Taif University, Turabah, Saudi Arabia

M. M. Soliman (✉)
Department of Biochemistry, Faculty of Veterinary Medicine, Benha University, P.O. 13736, Moshthohor, Benha, Egypt
e-mail: mohamedsoliman8896@yahoo.com

M. M. Soliman
e-mail: mohamed.soliman@fvtn.bu.edu.eg

A. A. Baiomy · M. H. Yassin
Biology Department, Faculty of Science, Taif University, Turabah, Saudi Arabia

A. A. Baiomy
Zoology Department, Faculty of Science, Cairo University, Giza, Egypt

M. H. Yassin
Reproductive Diseases Department, Animal Reproduction Research Institute, Al-Haram, Giza, Egypt

Keywords Curcumin · Lead intoxication · Immunoglobulins · Gene expression · Liver · Kidney · Histopathology

Introduction

Lead (Pb^{2+}) is known to be a heavy metal and potential environmental pollutant that induces toxicity for most of body organs [1]. The resistance to corrosion and low melting point of Pb^{2+} is the cause for its wide usage.

The importance of Pb^{2+} toxicity comes from its wide dispersion in ambient air, foods, drinking water, and consumption of vast quantities of lead as an antiknock agent in gasoline [1]. Several reports showed that Pb^{2+} caused many forms of illness to human organs [2].

It was reported that Pb^{2+} increased the level of lipid peroxidation and inhibited the activity of antioxidants, including glutathione-S-transferase (GST) and peroxidase (GPx), catalase, and superoxide dismutase (SOD) [2]. Generation of reactive oxygen species (ROS), and lipid peroxidation and depletion of antioxidant are the major contributors to Pb^{2+} exposure-related diseases [3]. The oxidative stress is a consequence of imbalance between oxidants and antioxidant enzymes [3]. Pb^{2+} is reported to cause oxidative stress by generating the release of ROS [4].

The absorbed Pb^{2+} is conjugated in the liver and passed to the kidney. Small quantity of Pb^{2+} is excreted in urine, and the rest accumulated in various body organs [5]. In chronic intoxication, the kidney and bone are the primary site for the accumulation of Pb^{2+} and the most critical organ that concentrates toxic substances in humans and animals, because of its highly specialized cells and large blood flow [6].

Curcumin (CUR) is an important natural compound, widely used in traditional diets and herbal medicine. Curcumin has various functions among which is anticancer, anti-inflammatory, antimicrobial, antiviral, antifungal, and antioxidant activity [7]. Curcumin has oxygen-free radical scavenger effects. It increases intracellular glutathione concentration, thereby protects lipid peroxidation, and reduces oxidative tissue damage [8]. Curcumin is safe without side effects and with pleiotropic functions [9]. It inhibits the generation of ROS [10]. Curcumin counters the toxicity induced by chemical carcinogens, as it induces the activity of detoxifying enzymes [11]. The potential molecular protective effects of curcumin on lead acetate-induced hepatotoxicity and nephrotoxicity have not been explored well. Therefore, the purpose of this study was to explore the protective effect of curcumin against lead acetate-induced changes in immunoglobulins, antioxidants, acute phase proteins, cytokines, podocytes integrity, and hepatorenal histopathological changes at cellular and molecular level.

Materials and Methods

Materials

Lead acetate, ethidium bromide, and agarose were purchased from Sigma-Aldrich (St. Louis, MO, USA). Curcumin was bought from local markets in Taif area,

Saudi Arabia. The male Wistar rats were purchased from King Fahd center for Scientific Research, King Abdel-Aziz University, Jeddah, Saudi Arabia. Serologic kits for glutamate pyruvate transaminase (GPT), glutamate oxalacetate transaminase (GOT), albumin, urea, and creatinine were purchased from *Bio-diagnostic Co.*, Dokki, Giza, Egypt. The deoxyribonucleic acid (DNA) ladder was purchased from MBI, Fermentas, Thermo Fisher Scientific, USA. Qiazol for RNA extraction and oligo dT primer was purchased from QIAGEN (Valencia, CA, USA).

Animals and Experimental Design

All animal procedures were approved by the Ethical Committee Office of the scientific dean of Taif University, Saudi Arabia. Forty male Wistar rats, 3 months old (250–280 g) were used for this study. For acclimatization, animals were kept under observation for 2 weeks before the onset of the experiment. The animals were kept at 12:12-h light–dark cycle and gained free access to food and water. Healthy rats were randomly divided into four groups as follows: Control group served as negative control and received corn oil orally and intraperitoneal injections (i.p; 1 mL/kg BW) of vehicle (120 mM NaCl, 10 mM phosphate buffer, pH 7.4). Lead acetate (LA) group injected i.p with LA in a dose of 50 mg/kg for 7 days. LA suspensions were prepared in 120 mM NaCl, 10 mM phosphate buffer, pH 7.4. Curcumin group (CUR) received curcumin dissolved in corn oil orally in a dose of 200 mg/kg BW for 4 weeks. Curcumin plus lead acetate group (CUR+LA) received curcumin orally for 3 weeks, and in the fourth week, curcumin was given 1 h before LA injection. To assess the short-term exposure to LA, the animals received their treatments for seven consecutive days. The dose of LA was determined based on other studies [9, 10, 12], while curcumin dose was determined based on another study [13]. The administrated doses of lead and curcumin were determined by other studies [9, 10, 12, 13] and are safe and enough to induce alteration without animals death based on reported studies. Twenty-four hours after administration of treatments, all animals were sacrificed after anesthetization by diethyl ether inhalation. Tissues from the liver and kidney were collected from slaughtered rats. Serum was extracted after blood centrifugation for 10 min at 5000 rpm. For gene expression, liver and kidney tissues were preserved in Qiazol reagent at -80°C for ribonucleic acid (RNA) extraction and in 10 % neutral buffered formalin (NBF) at room temperature for 24 h for histopathological examination.

Serum Biochemical Measurements

Serum levels of GPT, GOT, albumin, creatinine, and urea were measured spectrophotometrically using specific commercial kits (*Bio-diagnostic Co.*, Dokki, Giza, Egypt) and assayed according to the manufacturer's instruction manual.

Pb²⁺, IgG, IgM, and IgA Determinations

Blood lead levels were determined by atomic absorption spectrophotometry at Al-Asafara Laboratories Alexandria, Egypt. IgG, IgM, and IgA were measured on serum from rats using a radial immunodiffusion (RID) assay bought from *Clini Lab*, Al-Manial, Cairo, Egypt.

RNA Extraction, Complementary Deoxyribonucleic Acid Synthesis and Semiquantitative RT-PCR Analysis

Total RNA was extracted from liver and kidney (100 mg) of experimental rats. Samples were homogenized using homogenizer, and RNA was extracted using chloroform-isopropanol-alcohol method as previously described [14]. The RNA pellets were washed with 70 % ethanol then dried up. The pellet was dissolved in diethylpyrocarbonate (DEPC) water. RNA concentration was determined

spectrophotometrically at 260 nm. The RNA integrity was confirmed in 1.5 % denaturated agarose gel stained with ethidium bromide. RNA samples with ration between 1.7 and 1.9 were used for reverse transcription. A mixture of 2 µg of total RNA and 0.5 ng oligo dT primer (Qiagen Valencia, CA, USA) in a total volume of 11 µL sterilized DEPC water was incubated in the Bio-Rad T100™ Thermal cycle at 65 °C for 10 min for denaturation. Then, 2 µL of ×10 RT buffer, 2 µL of 10 mM dNTPs, and 100 U Moloney Murine Leukemia Virus (M-MuLV) Reverse Transcriptase (SibEnzyme. Ak, Novosibirsk, Russia) were added, and the total volume was completed up to 20 µL by DEPC water. The mixture was then re-incubated in Bio-Rad thermal cycle at 37 °C for 1 h and at 90 °C for 10 min for enzyme inactivation. For semiquantitative RT-PCR analysis, specific primers as reported in Table 1 were designed using Oligo-4 computer program and synthesized by Macrogen Company, GAsa-dong, Geumcheon-gu, Korea. PCR reaction was carried out in a total volume of 25 µL, consisting of 1 µL cDNA, 1 µL of 10 pM forward, and reverse primer, and 12.5 µL PCR Master Mix (Promega Corporation, Madison, WI, USA), and the volume was adjusted to 25 µL using sterilized deionized water. PCR cycles were initial denaturation at 94 °C for 5 min one cycle, followed by variable cycles. Each cycle consists

Table 1 PCR conditions for rat antioxidants, intermediate filament proteins, cytokines, and acute phase proteins genes

Examined genes	Product size (bp)	Annealing temp. (°C)	Number of cycles	Direction	Primer sequence (5'-3')
Desmin	398	54	35	Sense	TCACAATCACCTCTTTGTGGTC
				Antisense	CAGCACCTTCCAGTTCTCTCTT
Vimentin	444	55	35	Sense	GAGTCAAACGAATACCGGAGAC
				Antisense	GTGGTGCTGAGAAGTCTCATTG
GPx	406	57	30	Sense	AAGGTGCTGCTCATTGAGAATG
				Antisense	CGTCTGGACCTACCAGGAAGCTT
GST	575	55	30	Sense	GCTGGAGTGAGTTTGAAGAA
				Antisense	GTCCTGACCACGTCAACATAG
SOD	410	55	29	Sense	AGGATTAAGTGAAGGCGAGCAT
				Antisense	TCTACAGTTAGCAGGCCAGCAG
Catalase	652	55.5	31	Sense	GCGAATGGAGAGGCAGTGTAC
				Antisense	GAGTGACGTTGTCTTCATTAGCACTG
α-2 Macroglobulin	230	57	32	Sense	GCTCCTGTCTGTTTCCTTAGTT
				Antisense	ATTGGCCTTTCGTGGTTTAG
α1-Acid glycoprotein	325	55	32	Sense	GCTCCTGTCTGTTTCCTTAGTT
				Antisense	GGCTTTTGTGTGTTTGCTTCTATTTC
TGF-β1	456	60	35	Sense	TGAGTGGCTGTCTTTTGACG
				Antisense	TGGTTGTAGAGGGCAAGGAC
MCP-1	525	58	33	Sense	CAGGTCTCTGTCACGCTTCT
				Antisense	AGTATTTCATGGAAGGGAATAG
GAPDH	309	52	25	Sense	AGATCCACAACGGATACATT
				Antisense	TCCCTCAAGATTGTGACAA

of denaturation at 94 °C for 1 min, variable annealing temperature for each gene as shown in Table 1 and extension at 72 °C for 1 min, ended with final extension at 72 °C for 7 min. The expression of glyceraldehyde-3-phosphate dehydrogenase (GAPDH) messenger RNA (mRNA) was used as a reference for densitometric analysis. PCR products were visualized under UV light and photographed using gel documentation system. PCR products were run on DNA electrophoresis set with 1.5 % agarose gel (Bio Basic, Markham, ON, Canada) stained with ethidium bromide in Tris-Borate-EDTA (TBE) buffer. The intensity of bands of genes for five different rats per group was quantified densitometrically using ImageJ software version 1.47 (<http://imagej.en.softonic.com/>).

Histopathological Examination

The liver and kidney of male Wistar rats were collected at the end of experiment from tested groups. The samples were sliced and fixed in Bouin's solution, dehydrated in ascending grades of alcohols, cleared in xylene, and embedded in paraffin. The samples were casted, then sliced into 5 µm in thickness, and placed onto glass slides. The slides were stained with hematoxylin and eosin stains [15]. In Masson's Trichrome method, the liver and kidney were deparaffinized and rehydrated through descending series of alcohols and then stained in Biebrich scarlet-acid fuchsin solution. Then, sections were differentiated in phosphomolybdic-phosphotungstic acid solution. Sections were transferred directly to aniline blue solution and differentiated in 1 % acetic acid solution, dehydrated very quickly through ascending series of alcohols, cleared in xylene, and mounted with resinous mounting medium [16].

Statistical Analysis

Results are expressed as means±standard error of means (SEM). Data were analyzed using analysis of variance (ANOVA) and post hoc descriptive tests by SPSS software version 11.5 for Windows (SPSS, IBM, Chicago, IL, USA) with $P<0.05$ regarded as statistically significant. Regression analysis was performed using the same software.

Results

Serum Changes in Pb²⁺ Levels

Pb²⁺ was measured after i.p injection of lead acetate for 7 days. Pb²⁺ was low in control and curcumin-administered rats. The Pb²⁺ levels were 4.3±0.5 and 3.8±0.4 µg/dL, respectively. In lead acetate-injected rats, the Pb²⁺ levels were increased significantly ($P<0.05$) to 55±2.1 µg/dL. Prior administration of

Table 2 Protective effect of curcumin on lead acetate induced changes in serum levels of liver and kidney function biomarkers in Wistar rats

	Control	CUR	Pb	CUR + Pb
GOT (U/L)	45±8	43.7±9.6	89±9.1*	47.7±6.5 [#]
GPT(U/L)	51.3±3.9	52.7±5.01	94±7.2*	58±4.9 [#]
Albumin (g/dL)	5.2±0.6	6.1±0.7	2.8±0.2*	4.9±0.1 [#]
Urea (mg/dL)	45.6±5.8	46.3±6.3	80.0±10.5*	48.0±8.0 [#]
Creatinine (mg/dL)	0.9±5.8	1.0±0.3	2.4±0.5*	0.9±.08 [#]

Values are means±standard error (SEM) for three independent experiments per each treatment. Values are statistically significant at * $p<0.05$ vs. control and [#] $p<0.05$ vs. lead acetate group

curcumin for 3 weeks decreased significantly (20±1.1 µg/dL) the increase in Pb²⁺ levels reported in LA-injected rats.

Liver and Kidney Biomarkers

Serum levels of GPT and GOT were not changed in control and curcumin-administered rats (Table 2). Pb²⁺ injection induced twofold increase in GPT and GOT levels. Prior administration of curcumin ameliorated the reported increase in liver biomarkers (GPT and GOT) seen in LA-intoxicated rats. Albumin levels were decreased after LA injection, and prior curcumin administration prevented the decrease in albumin levels. Kidney biomarkers represented by urea and creatinine were increased after LA intoxication and prior curcumin administration normalized such increase when given with LA (Table 2).

IgG, IgA, and IgM Levels

The changes in IgG, IgA, and IgM are shown in Table 3. As seen, there is an overall decrease in serum levels of IgG, IgA, and IgM after injection of LA for 7 days. Prior administration of curcumin to LA-intoxicated rats inhibited the decrease in immunoglobulins levels. There was no significant difference between the control group and curcumin-administered rats (Table 3).

Table 3 Protective effect of curcumin on lead acetate-induced changes in serum immunoglobulin levels in Wistar rats

	Control	CUR	Pb	CUR+Pb
IgA (mg/dL)	39.6±2.9	44±3.1	25.7±2.1*	35.6±3.4 [#]
IgG (mg/L)	465±30.1	475±25.1	386±29.4*	474.9±22.6 [#]
IgM (mg/dL)	20.6±2.9	22.4±4.1	14.1±1.1*	19.6±1.2 [#]

Values are means±standard error (SEM) three independent experiments per each treatment. Values are statistically significant at * $p<0.05$ vs. control and [#] $p<0.05$ vs. lead acetate group

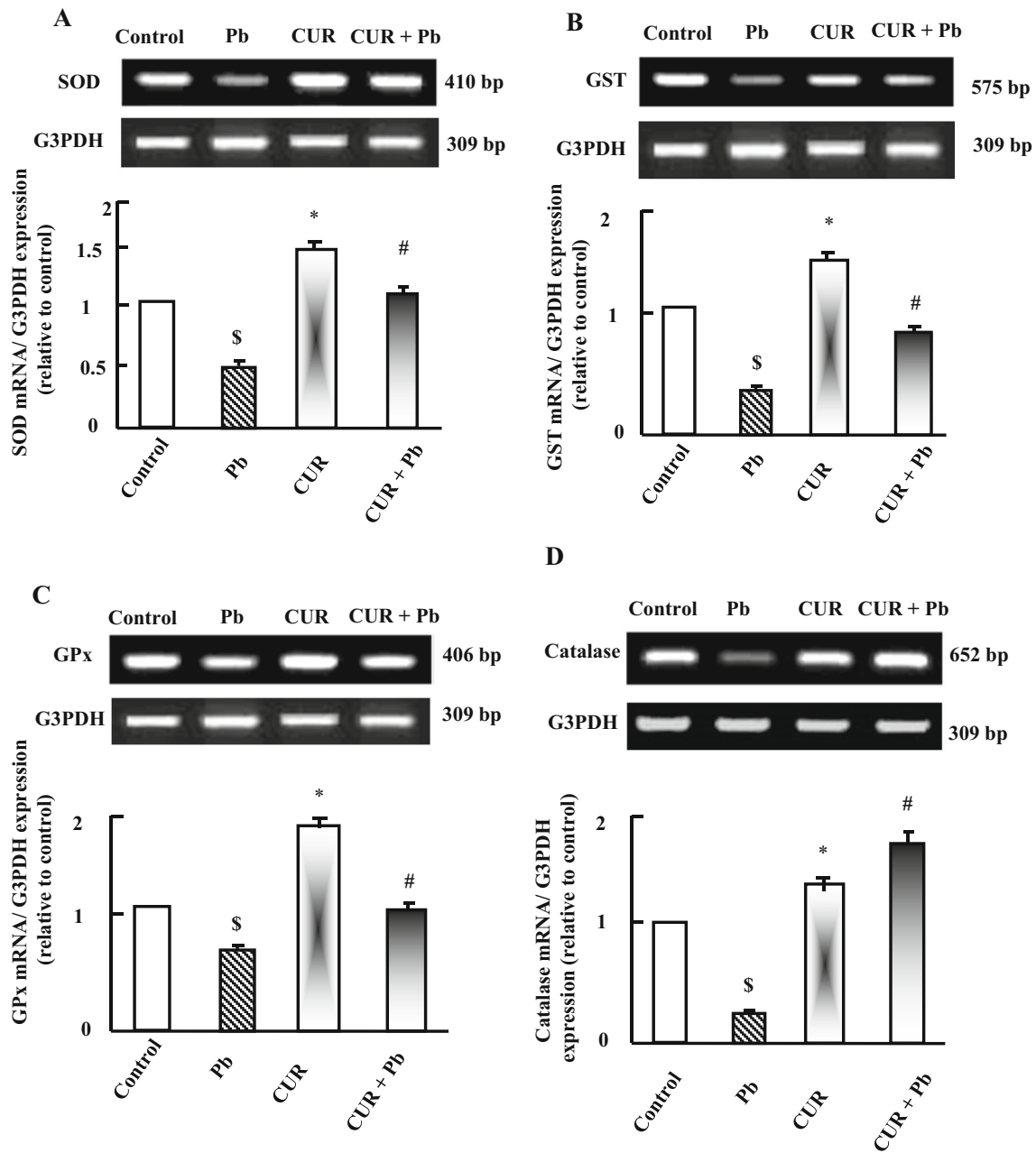


Fig. 1 Semiquantitative RT-PCR analysis of SOD (a), GST (b), GPx (c), and catalase (d) mRNA expressions and their corresponding GAPDH in the liver. Experimental groups were administered corn oil as a control (CTR), lead acetate (LA), curcumin (CUR), or curcumin plus LA (CUR+LA) as described in the “Materials and methods.” RNA was extracted and reverse-transcribed (1 µg), and RT-PCR analysis was carried out for SOD

(a), GST (b), GPx (c), and catalase (d) expression as described in the “Materials and methods.” Densitometric analysis was carried for three different experiments. Values are means±SEM obtained from 10 rats per group. * $P<0.05$ vs. control group, \$ $P<0.05$ vs. control and CUR-administered groups, and # $P<0.05$ vs. lead-intoxicated group

Protective Effect of Curcumin on Pb^{2+} -Induced Changes in Hepatic Antioxidants Expression

RT-PCR analysis for antioxidants expression is shown in Fig. 1a–d. The mRNA expressions of SOD, GST, GPx, and catalase were decreased significantly after LA injection for seven consecutive days. The expression of all antioxidants was increased in curcumin-administered group (Fig. 1a–d). Prior

and coadministration of curcumin plus LA reversed the decrease in antioxidants expression observed in LA-intoxicated rats.

Protective Effect of Curcumin on Pb^{2+} -Induced Changes in Hepatic Acute Phase Proteins Expression

To identify the possible involvement of curcumin against LA intoxication, the expressions of $\alpha 1$ -acid

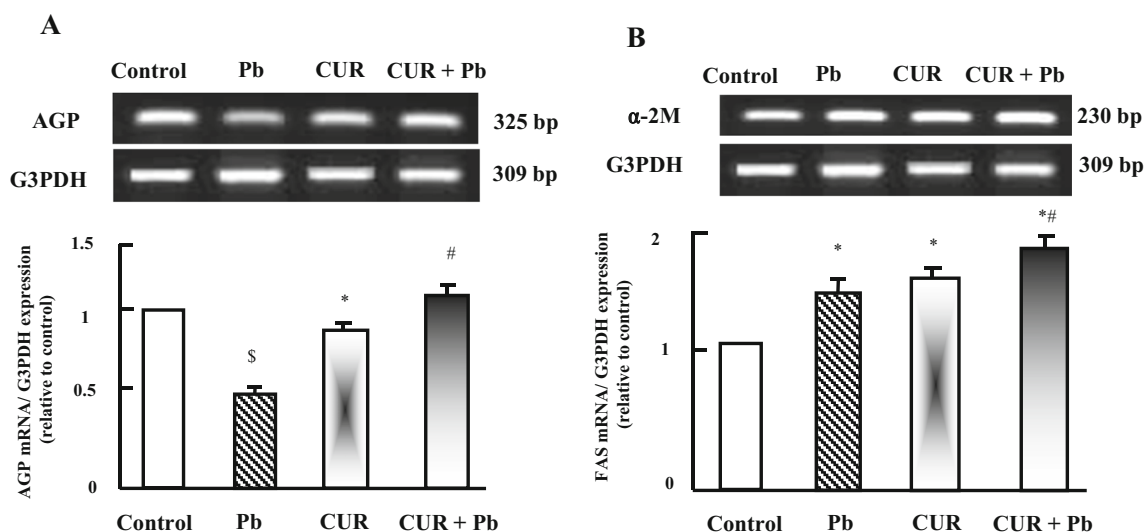


Fig. 2 Semiquantitative RT-PCR analysis of AGT (a) and α -2M (b) mRNA expressions and their corresponding GAPDH in the liver. Experimental groups were administered corn oil as a control (CTR), lead acetate (LA), curcumin (CUR), or curcumin plus LA (CUR+LA) as described in the “Materials and methods.” RNA was extracted and reverse-transcribed (1 μ g), and RT-PCR analysis was carried out for

AGT (a) and α -2M (b) expression as described in the “Materials and methods.” Densitometric analysis was carried for three different experiments. Values are means \pm SEM obtained from 10 rats per group. * P <0.05 vs. control group, \$ P <0.05 vs. control and CUR-administered groups, and # P <0.05 vs. lead-intoxicated group

glycoprotein (AGP) and α -2 macroglobulin (α -2M) were examined in the liver. AGP expression was decreased in LA-injected rats compared to control and curcumin-administered rats (Fig. 2a). Prior curcumin administration inhibited the changes in AGP expressions compared to LA-injected rats as shown in Fig. 2a.

Regarding α -2M mRNA expression, α -2M was increased in LA group compared to control administered rats. In parallel, curcumin increased α -2M expression. Prior curcumin administration induced additive stimulatory effect on α -2M expression compared to LA and control groups (Fig. 2b).

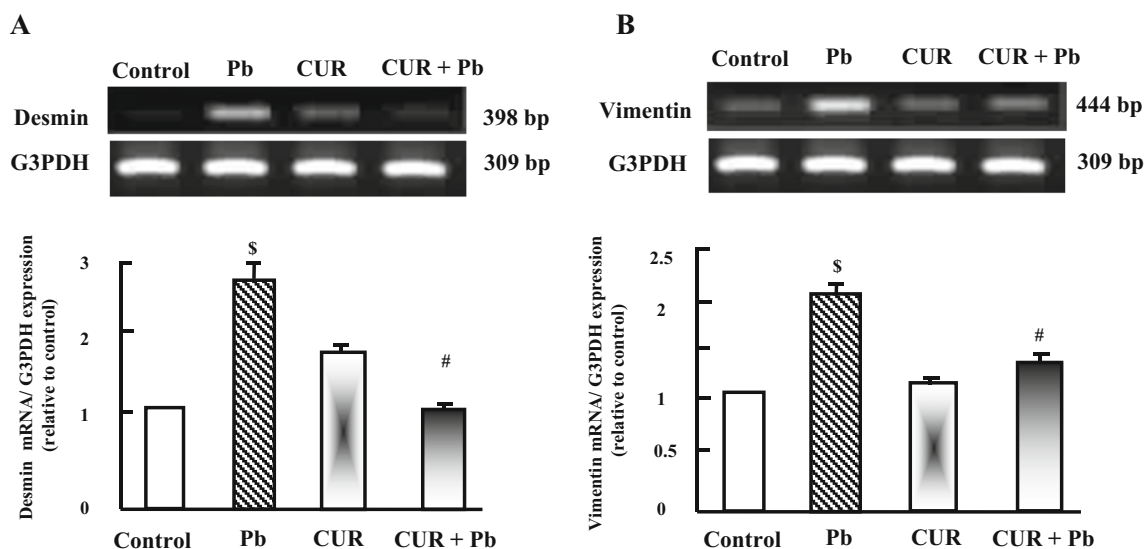


Fig. 3 Semiquantitative RT-PCR analysis of desmin (a) and vimentin (b) mRNA expressions and their corresponding GAPDH in the liver. Experimental groups were administered corn oil as a control (CTR), lead acetate (LA), curcumin (CUR), or curcumin plus LA (CUR+LA) as described in the “Materials and methods.” RNA was extracted and reverse-transcribed (1 μ g), and RT-PCR analysis was carried out for

desmin (a) and vimentin (b) expression as described in the “Materials and methods.” Densitometric analysis was carried for three different experiments. Values are means \pm SEM obtained from 10 rats per group. * P <0.05 vs. control group, * P <0.05 vs. control, and CUR-administered groups and # P <0.05 vs. lead-intoxicated group

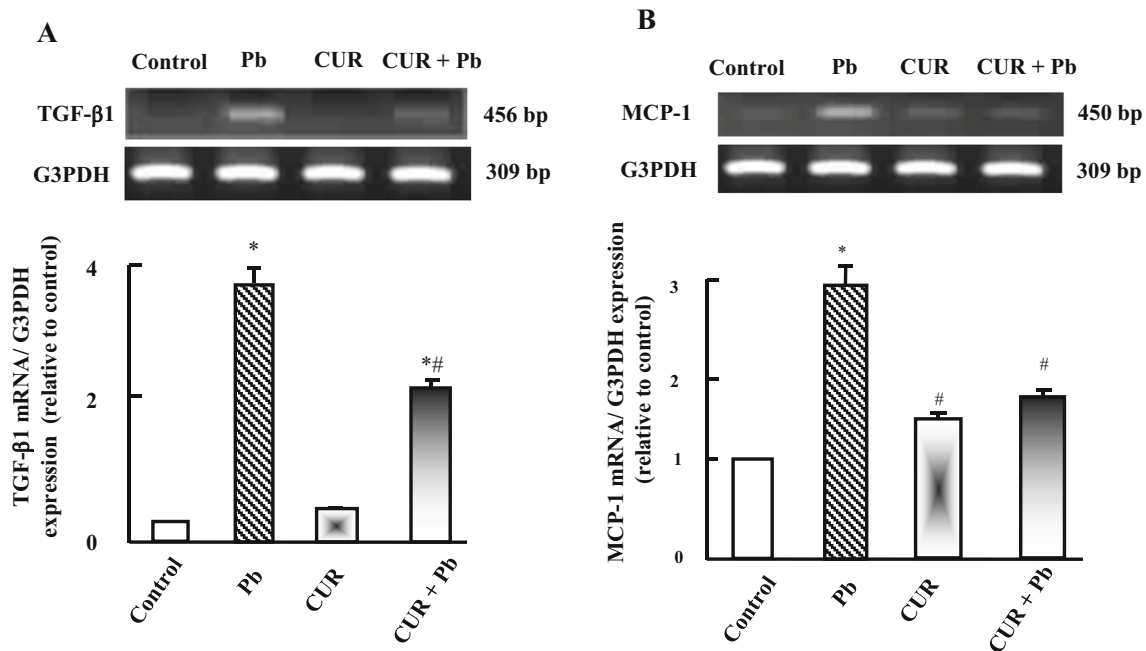


Fig. 4 Semiquantitative RT-PCR analysis of TGF-β1 (a) and MCP-1 (b) mRNA expressions and their corresponding GAPDH in the liver. Experimental groups were administered corn oil as a control (CTR), lead acetate (LA), curcumin (CUR), or curcumin plus LA (CUR+LA) as described in the “Materials and methods.” RNA was extracted and

reverse-transcribed (1 μg), and RT-PCR analysis was carried out for TGF-β1 (a) and MCP-1 (b) expression as described in “Materials and methods.” Densitometric analysis was carried for three different experiments. Values are means±SEM obtained from 10 rats per group. **P*<0.05 vs. control group and #*P*<0.05 vs. lead-intoxicated group

Protective Effect of Curcumin on Pb²⁺-Induced Changes in Renal Transforming Growth Factor-β1 and Monocyte Chemoattractant Protein-1 Expression

Lead intoxication induced significant upregulation (*P*<0.05) in the expression of transforming growth factor-β1 (TGF-β1) and monocyte chemoattractant protein-1 (MCP-1) compared to control and curcumin-administered rats (Fig. 3a–b). Curcumin alone has no effect on TGF-β1 and MCP-1 expressions. Prior and coadministration of curcumin reduced the upregulation in mRNA expression of TGF-β1 and MCP-1 shown in LA-intoxicated rats (Fig. 3).

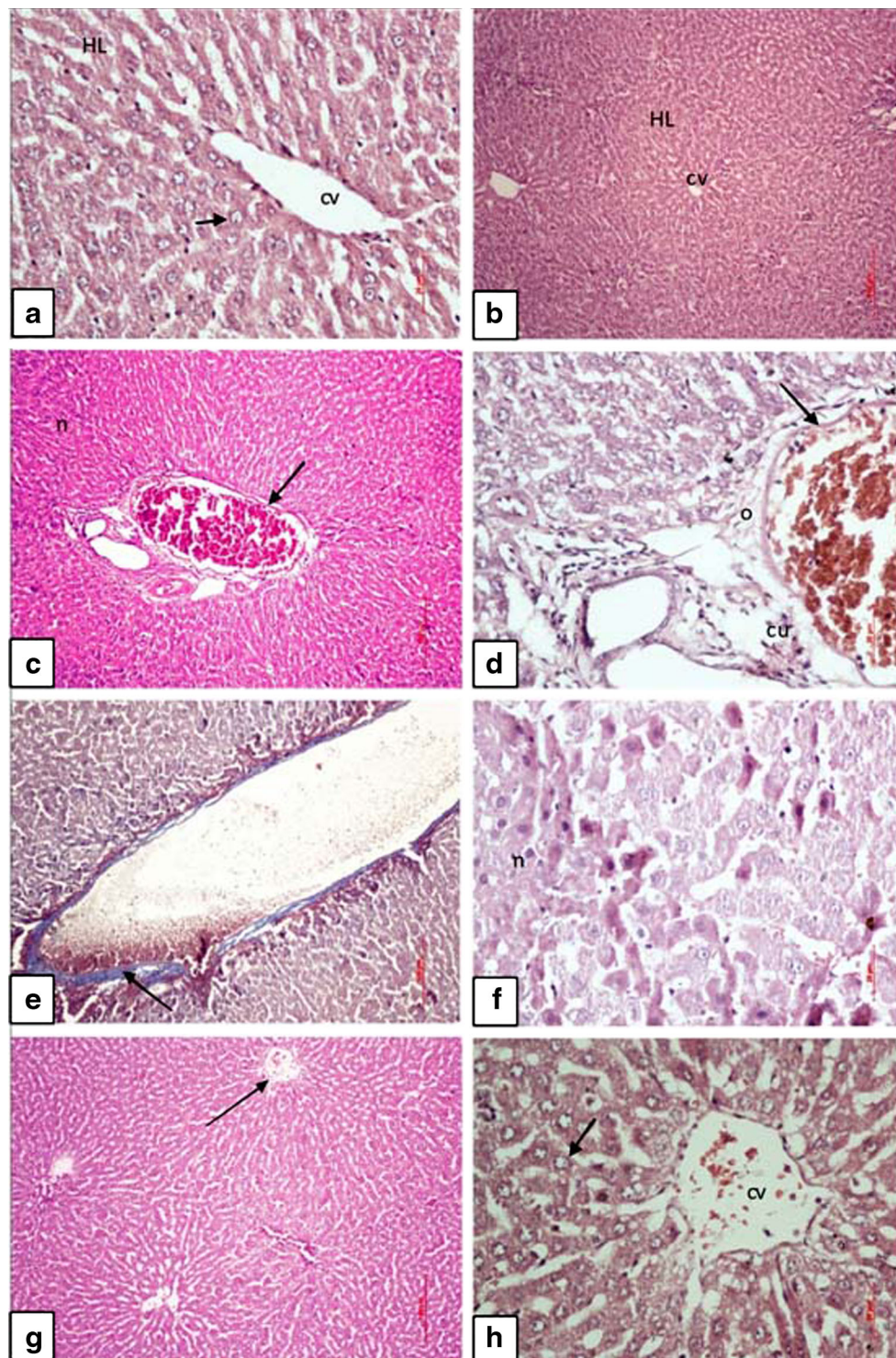
Protective Effect of Curcumin on Pb²⁺-Induced Changes in Renal Intermediate Filament Proteins Expression

To explore the harmful effect of LA on renal function efficiency, we examined the expression of some genes that are responsible for renal glomerular filtration rate. As seen in Fig. 4, LA-injected rats showed increase in mRNA expression of desmin and vimentin, known intermediate filament proteins that are essential for maintaining normal glomerular structure in kidney. Curcumin administration prior and during LA intoxicity inhibited the upregulation in mRNA expression of desmin and vimentin (Fig. 4a–b).

Protective Effect of Curcumin on Pb²⁺-Induced Changes in Liver and Kidney Histopathology

The liver of control and curcumin-administered rats showed normal hepatic structure, characterized by polygonal-shape hepatocytes with well-defined boundaries, slight staining acidophilic cytoplasm with large centrally located nucleus with dispersed chromatin radially disposed in the hepatic lobule, and the sinusoids arise in the periphery of the lobule are emptying in the direction of the central vein (Fig. 5a–b). The liver of LA-injected rats showed congestion of portal blood vessels with fibrous tissue proliferation and necrotic hepatocytes characterized by pyknotic nuclei with condensed chromatin (Fig. 5c), perivascular oedema, and perivascular cuffing of round cells with scattered necrotic hepatocytes (Fig. 5d–f). The liver of curcumin and LA-administered rats restored normal hepatic architecture that showed improvement in hepatocytes with mild congestion of central veins (Fig. 5g–h).

Regarding the renal changes occurred after LA intoxication, the kidney of control and curcumin-administered rats showed normal renal structure with well-organized glomerular structure surrounded by intact Bowman’s capsule, capsular space between the visceral and parietal layers with strongly acidophilic cytoplasm and spherical nuclei located in the center (Fig. 6a–b). The kidney of LA-intoxicated group showed hyaline casts in the lumen of renal-convoluted tubules with vacuolar degeneration of tubular epithelium and congestion of



renal blood vessels (Fig. 6c–d), perivascular fibrosis, oedema around congested blood vessels, and degenerated tubular epithelium (Fig. 6f). The kidney in curcumin and LA-administered rats showed restoration in normal nephron structure with mild congestion of renal blood vessel and mild intraluminal hyaline casts (Fig. 6g–h).

Discussion

The present study clarified, at least to our knowledge, that acute Pb^{2+} intoxication induced ameliorative changes and was protected by prior administration of curcumin. As known lead (Pb) is found in two main oxidation states (charges), Pb^{2+}

◀ **Fig. 5** Liver photomicrographs show the protective effect of curcumin on lead intoxication. **a** Liver of control rats showed normal hepatic architecture characterized by well-organized hepatic lobules (HL) which consisted of hepatic strands of radially disposed hepatocytes (arrow) surround central vein (cv): H&E (*bar*=20 μ m). **b** Rats administered with curcumin showed normal hepatic architecture characterized by well-organized hepatic lobules (HL) which consisted of hepatic strands of radially disposed hepatocytes surround central vein (cv): H&E (*bar*=100 μ m). **c** Rats intoxicated with LA showed congestion of portal blood vessels (arrow) with fibrous tissue proliferation and necrotic mass of hepatocytes (*n*): H&E (*bar*=100 μ m). **d** LA-intoxicated rats showed congestion of portal blood vessels (arrow) with perivascular oedema (*o*) and perivascular cuffing (*cu*): H&E (*bar*=20 μ m). **e** LA-intoxicated rats showed dilated portal blood vessel with perivascular fibrosis (arrow): Masson's trichrom (*bar*=100 μ m). **f** LA-intoxicated rats showed scattered necrotic hepatocytes (*n*) characterized by pyknotic nuclei and condensed chromatin: H&E (*bar*=20 μ m). **g** Liver of LA and curcumin-administered rats showed restored normal hepatic architecture with mild congestion of central vein (arrow): H&E (*bar*=100 μ m). **h** Liver of LA and curcumin-administered rats showed improvement in hepatocytes (arrow) and mild congestion of central vein: H&E (*bar*=20 μ m)

and Pb^{4+} , Pb^{2+} is the most common in blood where Pb^{4+} is the most common in acidic media and solutions. Blood pH is 7.2–7.4; therefore, the mostly measured form of Pb in blood and induced toxicity is Pb^{2+} [17]. LA intoxication showed (a) a decrease in serum immunoglobulins and liver damage as evidence by increase liver and kidney biomarkers, decrease in antioxidant gene expression, alterations in AGP and α -2M expression, and changes in liver histopathology, (b) upregulation in renal inflammatory cytokines (TGF- β 1), chemokines (MCP-1) and intermediate filament genes expression (desmin and vimentin), and (c) hepatic and renal histopathological changes and damage. Pb^{2+} is very dangerous to human body organs and the most toxic metal in the environment [2, 4, 18]. Exposure to Pb^{2+} is associated with cancer, neurotoxicity, hepatotoxicity, and cardiovascular disease [19].

The mechanism by which curcumin ameliorated Pb^{2+} toxicity is not examined well. Curcumin probably acts as lead chelating agent to form a molecular complex and to prevent the availability of lead and thus hinders Pb^{2+} entry and accumulation in the liver and renal tissues. As known, kidney is the prime excretory organ and the ultimate organ of clearance for most of the xenobiotics. Moreover, kidney is the most susceptible to lead toxicity [20]. We observed that prior and coadministration of curcumin for LA-intoxicated rats significantly protected the lipid peroxidation level from being increased as indicated by the upregulation in the mRNA expression of antioxidants examined. This infers that curcumin has antilipid peroxidation and antioxidative properties. Therefore, curcumin could protect against free radical-mediated oxidative and attenuates antioxidants depletion occurred by Pb^{2+} intoxication [21].

Generation of ROS caused renal and hepatic damage and consequently modified proteins, lipids, and DNA degradation [22]. Like kidney, liver is one of the targets for lead

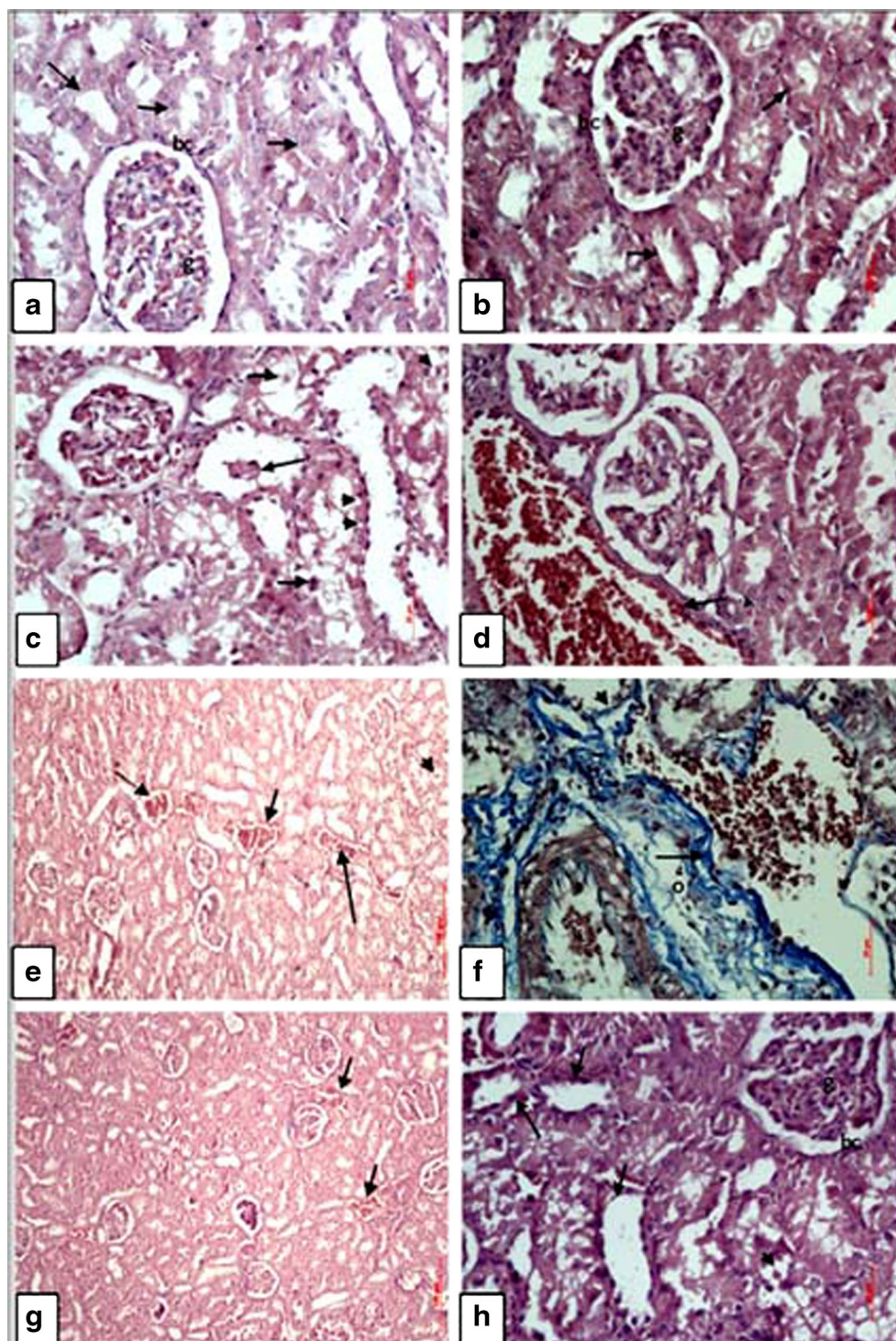
accumulation and responds to lead toxicity by increasing the activity of transaminases [23]. The present study showed increase in serum levels of GPT and GOT after lead intoxication, which coincides with the results of other studies [23, 24]. Curcumin inhibited LA-induced oxidative damage and decrease in antioxidants expression. Acute exposure to Pb^{2+} induces brain and kidney damage, and gastrointestinal diseases, while chronic exposure caused adverse effects on the blood, central nervous system, blood pressure, kidneys, and vitamin D metabolism [25]. These findings are compatible with other studies using curcumin against variable toxic materials [25, 26]. In this study, curcumin normalized the downregulation in antioxidants expression in LA-intoxicated rats as reported by this and other studies [26, 27]. The normalizing effects of curcumin may be due to the increase in hepatic content of polyphenolic compounds of curcumin, as two possible mechanisms can be proposed, first is scavenging ROS and second is chelating lead acetate [18].

Pb^{2+} showed significant declines in IgM, IgG, and IgA levels in lead-exposed rats. Probably, lead has the ability to affect B cell function due to increase in oxidative stress [28]. Such oxidative stress induced by LA causes an alteration in cytokine expression, consequently promotes Th cell dysregulation, and alters the availability of key Th1 and Th2 cytokines [28].

AGP is an acute phase protein synthesized primarily in hepatocytes and is affected by many factors such as pregnancy, certain drugs, and certain diseases [29]. The pharmacokinetics of some drugs is mediated by AGP to reduce the degree of toxicity and inflammation in tissues [30]. We reported that LA intoxication decreased AGP expression due to inflamed hepatocytes, and curcumin normalized it. Moreover, α -2M is slightly increased after LA intoxication and curcumin alone upregulated it. Of interest, prior administration of curcumin induced additive upregulation in α -2M expression. The cause for α -2M upregulation is probably a counteract mechanism to inhibit plasmin synthesis occurred after LA intoxication and to increase the transport of growth factors that may help in hepatocyte regeneration [31].

Podocytes is the most critical components in the kidney maintain glomerular structure in the kidney. Podocytes control the bulk flow of filtrate through the intracellular spaces and are situated at the basement of glomeruli as the terminal element in ultrafiltration barrier [32]. Injury of podocytes causes focal segmental glomerulosclerosis and chronic renal diseases [33]. Podocytes express unusual intermediate filament proteins (IFs) for visceral epithelial cells. IFs are mainly composed of vimentin, nestin, desmin, synaptopodin, and connexin 43. Tissue injury is often associated with changes in gene expression of IFs [34]. LA-intoxicated rats showed upregulation in expression of desmin and vimentin. Curcumin downregulated IFs expression to maintain podocyte stability and normal renal barrier. Podocytes are generally attached to several capillaries

Fig. 6 Renal photomicrographs show the protective effect of curcumin on lead intoxication. **a** Control rats showed normal glomerular structure (g) with intact Boman's capsule (bc) and normal renal tubular structures (arrows); H&E (bar=20 μ m). **b** Kidney of curcumin-administered rats showed normal nephron architecture characterized by well-organized glomerular (g) and tubular (arrows) structures; H&E (bar=20 μ m). **c** Kidney of LA-intoxicated rats showed intraluminal hyaline casts (arrow) and vacuolar degeneration of tubular epithelium (arrow heads); H&E (bar=20 μ m). **d** Kidney of LA-intoxicated rats showed congestion of renal blood vessels (arrow); H&E (bar=20 μ m). **e** LA-intoxicated rats showed congestion of renal blood vessel (arrows) and hyaline casts (short arrow); H&E (bar=100 μ m). **f** LA-intoxicated rats showed perivascular fibrosis (arrow), oedema (o) around congested renal blood vessel, and degenerated tubular epithelium (arrow head); Masson's trichrom (bar=20 μ m). **g** Kidney of LA and curcumin-administered rats showed restored normal nephron structure with mild congestion of renal blood vessels (arrows); H&E (bar=100 μ m). **h** Kidney of LA and curcumin-administered rats showed renal tubular structure (arrows) and mild hyaline casts (arrow head); H&E (bar=20 μ m)



by way of their foot and primary processes to increase the mechanical resistance of cells [35]. The upregulation of IFs allows podocytes to progress to cell hypertrophy, which are suitable for glomerular growth but prior administration of curcumin-inhibited IFs expression upregulated by LA to maintain renal barrier and normal renal function. For our knowledge, we are the first whom explained the effect of Pb^{2+} intoxication on IFs gen expressions.

Cytokines and chemokines are proteins produced by many cell types, and the imbalance expression of cytokines has been implicated in the progression of many diseases [36]. TGF- β 1 is the early mediator of the inflammatory response in most species [37]. Pb^{2+} intoxication upregulated TGF- β 1 expression, and curcumin administration downregulate it to control the degree of inflammation. It has been shown that curcumin decreased mRNA expression of IL-1 β , TNF- α , and IL-8

increased after liver toxicity [14]. In the current results, curcumin regulated MCP-1 expression in a way to initiate chemoattractant mechanism and consequently ameliorate inflammation. The reduction of the $\text{I}\kappa\text{B}/\text{NF-}\kappa\text{B}$ signaling pathway is the cause for the inhibitory effect of curcumin on inflammatory cytokines [37]. The increase in $\text{TGF-}\beta 1$ expression in Pb^{2+} intoxicated rats is due to fibrosis occurred after Pb^{2+} intoxication [38]. On the other hand, MCP-1 is produced by several cell types and is stimulated by LPS and inflammatory cytokines. Monocyte recruitment is induced by MCP-1 [39]. MCP-1 expression is upregulated by LA intoxication and inhibited by prior curcumin administration, confirming its anti-inflammatory effects and initiation of monocytes recruitment.

In short, LA-intoxicated rats showed adverse degenerative effects on the liver and kidney structure that may be due to induced oxidative stress relative to control. Such degenerative changes were reported in female albino rats after lead exposure and were due to oxidative damage and ROS of both kidney and liver [40]. There are reports of antioxidant, radical scavenging, and metal chelating effects of curcumin on various forms of metal toxicity [40–42]. In our study, curcumin showed acceptable mitigative protective effect against histopathological changes occurred in liver and kidney through regulation of AGP, α -2M, $\text{TGF-}\beta 1$, and MCP-1 expression.

Conclusions

The results from this study clarified that lead intoxication induced oxidative stress, immunosuppressive effects, and alteration in gene expression of antioxidants, intermediate filament proteins, cytokines, and acute phase proteins in the kidney and liver. Moreover, it caused renal and liver histopathological changes. Prior treatment with curcumin could significantly attenuate the lead-induced immunosuppressive, oxidative stress, and nephrotoxicity and hepatotoxicity.

Acknowledgments We greatly appreciate the contributions of all authors to finish this study.

Conflict of Interest Authors declare no conflict of interests.

Financial Disclosure There is no financial support for this study and was supported on author's expenses.

References

- Landrigan PJ, Boffetta P, Apostoli P (2000) The reproductive toxicity and carcinogenicity of lead: a critical review. *Am J Ind Med* 38:231–243
- Ercal N, Gurer-Orhan H, Aykin-Burns N (2001) Toxic metals and oxidative stress part I: mechanisms involved in metal-induced oxidative damage. *Curr Top Med Chem* 1:529–539. doi:10.2174/1568026013394831
- Silbergeld EK, Waalkes M, Rice JM (2000) Lead as a carcinogen: experimental evidence and mechanisms of action. *Am J Ind Med* 38: 316–323
- El-Nekeety AA, El-Kady AA, Soliman MS, Hassan NS, Abdel-Wahhab MA (2009) Protective effect of *Aquilegia vulgaris* (L.) against lead acetate-induced oxidative stress in rats. *Food Chem Toxicol* 47:2209–15. doi:10.1016/j.fct.2009.06.019
- Flora SJS, Mittal M, Mehta A (2008) Heavy metal induced oxidative stress and its possible reversal by chelation therapy. *Indian J Med Res* 128:501–23
- Kuhad A, Pilkhwai S, Sharma S, Tirkey N, Chopra K (2007) Effect of curcumin on inflammation and oxidative stress in cisplatin-induced experimental nephrotoxicity. *J Agric Food Chem* 55: 10150–10155. doi:10.1021/jf0723965
- Joe B, Vijaykumar M, Lokesh BR (2004) Biological properties of curcumin-cellular and molecular mechanisms of action. *Crit Rev Food Sci Nutr* 44:97–111. doi:10.1080/10408690490424702
- Okada K, Wangpoengtrakul C, Tanaka T, Toyokuni S, Uchida S, Osawa T (2001) Curcumin and especially tetrahydrocurcumin ameliorate oxidative stress-induced renal injury in mice. *J Nutr* 131: 2090–2095
- Conterato GMM, Augusti PR, Somacal S, Einsfeld L, Sobieski R, Torres JR (2007) Effect of lead acetate on cytosolic thioredoxin reductase activity and oxidative stress parameters in rat kidneys. *Basic Clin Pharmacol Toxicol* 101:96–100
- Conterato GM, Quattrin A, Somacal S, Ruviano AR, Vicentini J, Augusti PR et al (2014) Acute exposure to low lead levels and its implications on the activity and expression of cytosolic thioredoxin reductase in the kidney. *Basic Clin Pharmacol Toxicol* 114:476–84. doi:10.1111/bcpt.12183
- Abdou HM, Hassan MA (2014) Protective role of omega 3 polyunsaturated fatty acid against lead acetate induced toxicity in liver of female rats. *Biomed Res Int* 2014:435857. doi:10.1155/2014/435857
- Fu Y, Zheng S, Lin J, Ryerse J, Chen A (2008) Curcumin protects the rat liver from CCl_4 caused injury and fibrogenesis by attenuating oxidative stress and suppressing inflammation. *Mol Pharmacol* 73: 399–409
- Garcia-Nino W, Tapia E, Zazueta C, Barrón Z, Pando R, García C et al (2013) Curcumin Pretreatment Prevents Potassium Dichromate-Induced Hepatotoxicity, Oxidative Stress, Decreased Respiratory Complex I Activity, and Membrane Permeability Transition Pore Opening. *J Evi Com Med* 1–19. doi:10.1155/2013/424692
- Soliman MM, Nassan MA, Ismail TA (2014) Immunohistochemical and molecular study on the protective effect of curcumin against hepatic toxicity induced by paracetamol in Wistar rats. *BMC Complement Altern Med* 14:457. doi:10.1186/1472-6882-14-457
- Wilson I, Gamble M (2008) The hematoxylin and eosins. In: Bancroft JD, Gamble M (eds) *Theory and practice of histological techniques*. Elsevier Health Sciences, London, UK; ISBN-10. www.expertconsultbook.com/expertconsult/.../linkTo
- Carson F (1990) *Histotechnology: a self-instructional text*. 3rd edn. ASCP Press, Chicago, ISBN-10: 0891895817. P 400. www.ascp.org/.../Histotechnology-A-Self-Instructional-Text-3rd-Edition
- Polyanskiy NG, Fillipova NA ed. (1986) *Analytical chemistry of the elements: lead*. P.22
- Ercal N, Neal R, Treeratphan P, Lutz PM, Hammond TC, Dennery PA et al (2000) A role for oxidative stress in suppressing serum immunoglobulin levels in lead exposed Fisher 344 rats. *Arch Environ Contam Toxicol* 39:251–6
- Williams BJ, Hejtmancik MR, Abreu M (1983) Cardiac effects of lead. *Fed Proc* 42:2989–2993
- Jarrar BM (2003) Histological and histochemical alterations in the kidney induced by lead. *Ann Saudi Med* 23:10–15

21. Del Rio D, Stewart AJ, Pellegrini N (2005) A review of recent studies on malondialdehyde as toxic molecule and biological marker of oxidative stress. *Nutr Metab Cardiovasc Dis* 15:316–28. doi:[10.1016/j.numecd.2005.05.003](https://doi.org/10.1016/j.numecd.2005.05.003)
22. Halliwell B, Gutteridge J (1990) Role of free radicals and catalytic metal ions in human disease: an overview. *Methods Enzymol* 186:1–85. doi:[10.1016/0076-6879\(90\)86093-B](https://doi.org/10.1016/0076-6879(90)86093-B)
23. Mehana EE, Meki AR, Fazili KM (2012) Ameliorated effects of green tea extract on lead induced liver toxicity in rats. *Exp Toxicol Pathol* 64:291–295. doi:[10.1016/j.etp.2010.09.001](https://doi.org/10.1016/j.etp.2010.09.001)
24. Chiang H, Chang H, Yao P, Chen Y, Jeng K, Wang J et al (2014) Sesamin reduces acute hepatic injury induced by lead coupled with lipopolysaccharide. *J Chin Med Assoc* 77:227–233. doi:[10.1016/j.jcma.2014.02.010](https://doi.org/10.1016/j.jcma.2014.02.010)
25. Ansari MA, Maayah ZH, Bakheet SA, El-Kadi AO, Korashy HM (2013) The role of aryl hydrocarbon receptor signaling pathway in cardiotoxicity of acute lead intoxication in vivo and in vitro rat model. *Toxicology* 306:40–49. doi:[10.1016/j.tox.2013.01.024](https://doi.org/10.1016/j.tox.2013.01.024)
26. Mathews V, Binu P, Sauganth-Paul M, Abhilash M, Manju A, Nair R (2012) Hepatoprotective efficacy of curcumin against arsenic trioxide toxicity. *Asian Pac J Trop Biomed* 2:S706–S711. doi:[10.1016/S2221-1691\(12\)60300-1](https://doi.org/10.1016/S2221-1691(12)60300-1)
27. García-Niño WR, Pedraza-Chaverrí J (2014) Protective effect of curcumin against heavy metals-induced liver damage. *Food Chem Toxicol* 69:182–201. doi:[10.1016/j.fct.2014.04.016](https://doi.org/10.1016/j.fct.2014.04.016)
28. Hsiao CL, Wu KH, Wan KS (2011) Effects of environmental lead exposure on T-helper cell-specific cytokines in children. *J Immunotoxicol* 8:284–287. doi:[10.3109/1547691X.2011.592162](https://doi.org/10.3109/1547691X.2011.592162)
29. Colombo S, Buclin T, Décosterd LA, Telenti A, Furrer H, Lee BL et al (2006) Orosomucoid (alpha1-acid glycoprotein) plasma concentration and genetic variants: effects on human immunodeficiency virus protease inhibitor clearance and cellular accumulation. *Clin Pharmacol Ther* 80:307–318
30. Anderson SP, Cattley RC, Corton JC (1999) Hepatic expression of acute-phase protein genes during carcinogenesis induced by peroxisome proliferators. *Mol Carcinog* 26:226–238
31. Lyoumi S, Tamion F, Petit J, Déchelotte P, Dauguet C, Scotté M et al (1998) Induction and modulation of acute-phase response by protein malnutrition in rats: comparative effect of systemic and localized inflammation on interleukin-6 and acute-phase protein synthesis. *J Nutr* 128:166–174
32. Fries JW, Sandstrom DJ, Meyer TW, Rennke HG (1989) Glomerular hypertrophy and epithelial cell injury modulate progressive glomerulosclerosis in the rat. *Lab Invest* 60:205–218
33. Kriz W, Gretz N, Lemley KV (1998) Progression of glomerular diseases: is the podocyte the culprit? *Kidney Int* 54:687–697
34. DePianto D, Coulombe PA (2004) Intermediate filaments and tissue repair. *Exp Cell Res* 301:68–76
35. Omary MB, Coulombe PA, McLean WH (2004) Intermediate filament proteins and their associated diseases. *N Engl J Med* 351:2087–2100
36. Arend W, Gab C (2004) Cytokines in the rheumatic diseases. *Rev Rheumatol Dis Clin North Am* 30:41–67
37. Jobin C, Braham C, Russo MP, Juma B, Narula AS, Brenner DA et al (1999) Curcumin blocks cytokine-mediated NF- κ B activation and proinflammatory gene expression by inhibiting inhibitory factor I- κ B kinase activity. *J Immunol* 163:3474–3483
38. Qiao YF, Jiang YS, Pang DZ (2006) Expression of renal nuclear factor-kappa B, transforming growth factor-beta and fibronectin of rats exposed to lead. *Zhonghua Lao Dong Wei Sheng Zhi Ye Bing Za Zhi* 3:139–42
39. Gerdprasert O, O'Bryan MK, Nikolic-Paterson DJ, Sebire K, de Kretser DM, Hedger MP (2002) Expression of monocyte chemoattractant protein-1 and macrophage colony-stimulating factor in normal and inflamed rat testis. *Mol Hum Reprod* 8:518–24
40. Ghoniem M, El-Sharkawy N, Hussein M, Moustafa G (2012) Efficacy of Curcumin on Lead Induced Nephrotoxicity in Female Albino Rats. *Am Sci J* 8:502–510. www.jofamericanscience.org/journals/.../064_8969am0806_502_510.pdf
41. Agarwal R, Goel SK, Behari JR (2010) Detoxification and antioxidant effects of curcumin in rats experimentally exposed to mercury. *J Appl Toxicol* 30:457–468. doi:[10.1002/jat.1517](https://doi.org/10.1002/jat.1517)
42. Flora G, Gupta D, Tiwari A (2012) Toxicity of lead: a review with recent updates. *Interdiscip Toxicol* 5:47–58. doi:[10.2478/v10102-012-0009-2](https://doi.org/10.2478/v10102-012-0009-2)